



Material suplementario

---

## **Integración de la imagen mecánica, estructural y eléctrica para entender la respuesta a la terapia de resincronización cardiaca**

Etelvino Silva, Bart Bijnens, Antonio Berruezo, Lluís Mont, Adelina Doltra,  
David Andreu, Josep Brugada y Marta Sitges

*Servicio de Cardiología, Institut del Tórax, Hospital Clínic, Institut d'Investigacions  
Biomèdiques August Pi i Sunyer (IDIBAPS), Universitat de Barcelona, Barcelona, España*

---

## **EFFECT OF CARDIAC RESYNCHRONIZATION THERAPY**

With optimized cardiac resynchronization therapy, the onset of electrical propagation for patients with left ventricular preactivation ( $VV = -30$  ms,  $n = 4$ ) was at the lateral left ventricular wall, while the septum was the last segment to be activated in all patients. Patients with an optimized simultaneous biventricular pacing ( $n = 8$ ) showed a different pattern, with onset of the electrical activation at the posterior left ventricular wall and at the apex, while wide variability existed in the last electrically activated left ventricular segment (Figures 1-8 from Supplementary Material).

Analyzing the pattern of the maximal mechanical motion spread with the optimized device, there was also wide variability between patients; the first segments to reach the maximum motion with left ventricular preactivation were the lateral wall in 2 patients and the septoapical segment in the remainder (Figures 2, 12 from Supplementary Material). The last segments also showed wide variability, being the posterior, septal, inferior or the anterior walls. Regarding those patients with simultaneous biventricular pacing, the first left ventricular segment to reach the maximum motion was the lateral wall in 3 patients, the apex in another other 3, and the septal and the inferior left ventricular walls in the remainder. The last segment to reach the minimum systolic volume was the inferior wall in 4 patients, the posterior wall in 2, and the anterior and septal walls for the remainder.

**SUPPLEMENTARY MATERIAL FIGURE LEGENDS**

A) LV dysfunction

Time step=5ms

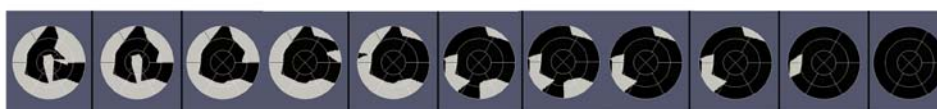

Time step=16ms



B) LV dysfunction after CRT optimization

Time step=5ms



Time step=9ms



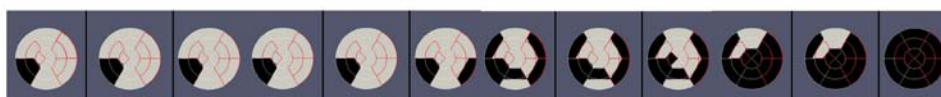**Figure 1.** Sequences of electrical activation (upper bull's-eye maps) from the electrical onset (left) to the end (right) and maximal mechanical motion (lower bull's-eye maps) from the first segment (left) to the last segments to reach minimal volume from a responder patient: A) left ventricular systolic dysfunction without transmural scar and with anterolateral propagation line block. B) Electrical and mechanical bull's eyes of the same patients after cardiac resynchronization therapy showing a significant decrease in the timing and propagation of both electrical activation and mechanical timings with cardiac resynchronization therapy and how the patterns are changed. CRT, cardiac resynchronization therapy; LV, left ventricular.

A) LV dysfunction

Time step=5ms



Time step=16ms



B) LV dysfunction after CRT optimization

Time step=5ms



Time step=12ms



**Figure 2.** Sequences of electrical activation (upper bull's-eye maps) from the electrical onset (left) to the end (right) and maximal mechanical motion (lower bull's-eye maps) from the first segment (left) to the last segments to reach minimal volume from a responder patient: A) Left ventricular systolic dysfunction without transmural scar but septal and lateral scar. B) Electrical and mechanical bull's eyes of the same patients after cardiac resynchronization therapy showing a decrease in the timing and propagation of both electrical activation and mechanical timings with cardiac resynchronization therapy and how the patterns are changed. Red lines represent left ventricular segments with myocardial scar. CRT, cardiac resynchronization therapy; LV, left ventricular.

### A) LV dysfunction

Time step=5ms



Time step=11ms



### B) LV dysfunction after CRT optimization

Time step=5ms



Time step=9ms



**Figure 3.** Sequences of electrical activation (upper bull's-eye maps) from the electrical onset (left) to the end (right) and maximal mechanical motion (lower bull's-eye maps) from the first segment (left) to the last segments to reach minimal volume from a responder patient: A) Left ventricular systolic dysfunction without transmural scar and with anterolateral propagation line block. B) Electrical and mechanical bull's eyes of the same patients after cardiac resynchronization therapy showing a significant decrease in the timing and propagation of both electrical activation and mechanical timings with cardiac resynchronization therapy and how the patterns are changed. CRT, cardiac resynchronization therapy; LV, left ventricular.

A) LV dysfunction

Time step=5ms



Time step=12ms



B) LV dysfunction after CRT optimization

Time step=5ms



Time step=8ms




**Figure 4.** Sequences of electrical activation (upper bull's-eye maps) from the electrical onset (left) to the end (right) and maximal mechanical motion (lower bull's-eye maps) from the first segment (left) to the last segments to reach minimal volume from a responder patient: A) Left ventricular systolic dysfunction without transmural scar. B) Electrical and mechanical bull's eyes of the same patients after cardiac resynchronization therapy showing a decrease in the timing and propagation of both electrical activation and mechanical timings with cardiac resynchronization therapy and how the patterns are changed. CRT, cardiac resynchronization therapy; LV, left ventricular.

### A) LV dysfunction: Scar tissue

Time step=5ms



Time step=11ms




### B) LV dysfunction after CRT optimization: Scar tissue

Time step=5ms




Time step=8ms



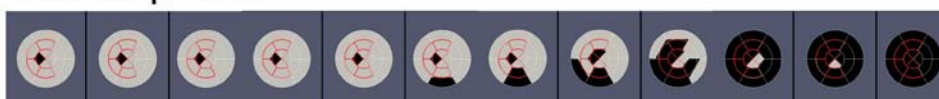**Figure 5.** Sequences of electrical activation (upper bull's-eye maps) from the electrical onset (left) to the end (right) and maximal mechanical motion (lower bull's-eye maps) from the first segment (left) to the last segments to reach minimal volume from a responder patient: A) Left ventricular systolic dysfunction with transmural scar. B) Electrical and mechanical bull's eyes of the same patients after cardiac resynchronization therapy showing a significant decrease in the timing and propagation of both electrical activation and mechanical timings with cardiac resynchronization therapy and how the patterns are changed. Red lines represent left ventricular segments with myocardial scar. CRT, cardiac resynchronization therapy; LV, left ventricular.

A) LV dysfunction: Scar tissue

Time step=5ms



Time step=9ms



B) LV dysfunction after CRT optimization: Scar tissue

Time step=5ms



Time step=11ms



**Figure 6.** Sequences of electrical activation (upper bull's-eye maps) from the electrical onset (left) to the end (right) and maximal mechanical motion (lower bull's-eye maps) from the first segment (left) to the last segments to reach minimal volume from a non-responder patient: A) Left ventricular systolic dysfunction with transmural scar. B) Electrical and mechanical bull's eyes of the same patients after cardiac resynchronization therapy showing a decrease just in the timing and propagation of electrical activation with cardiac resynchronization therapy. Red lines represent left ventricular segments with myocardial scar. CRT, cardiac resynchronization therapy; LV, left ventricular.

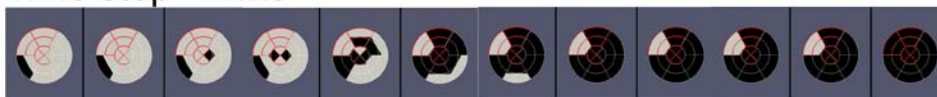

### A) LV dysfunction: Scar tissue

Time step=5ms




Time step=14ms



### B) LV dysfunction after CRT optimization: Scar tissue

Time step=5ms



Time step=10ms



**Figure 7.** Sequences of electrical activation (upper bull's-eye maps) from the electrical onset (left) to the end (right) and maximal mechanical motion (lower bull's-eye maps) from the first segment (left) to the last segments to reach minimal volume from a non-responder patient: A) Left ventricular systolic dysfunction with transmural scar. B) Electrical and mechanical bull's eyes of the same patients after cardiac resynchronization therapy showing a slight decrease in the timing and propagation of both electrical activation and mechanical timings with cardiac resynchronization therapy. Red lines represent left ventricular segments with myocardial scar. CRT, cardiac resynchronization therapy; LV, left ventricular.

### A) LV dysfunction: Scar tissue

Time step=5ms




Time step=14ms

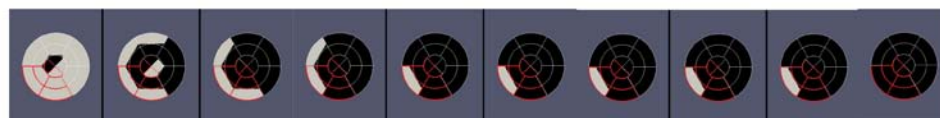

### B) LV dysfunction after CRT optimization: Scar tissue

Time step=5ms



Time step=16ms



**Figure 8.** Sequences of electrical activation (upper bull's-eye maps) from the electrical onset (left) to the end (right) and maximal mechanical motion (lower bull's-eye maps) from the first segment (left) to the last segments to reach minimal volume from a non-responder patient: A) Left ventricular systolic dysfunction with transmural scar at the posterior wall. B) Electrical and mechanical bull's eyes of the same patients after cardiac resynchronization therapy showing a slight decrease in the timing and propagation just of electrical activation with cardiac resynchronization therapy. Red lines represent left ventricular segments with myocardial scar. CRT, cardiac resynchronization therapy; LV, left ventricular.

A) LV dysfunction

Time step=5ms

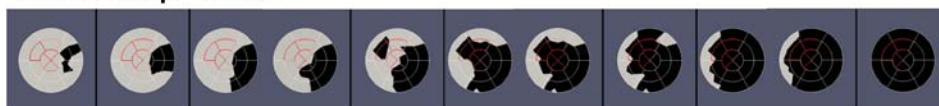

Time step=11ms



B) LV dysfunction after CRT optimization

Time step=5ms



Time step=7ms



**Figure 9.** Sequences of electrical activation (upper bull's-eye maps) from the electrical onset (left) to the end (right) and maximal mechanical motion (lower bull's-eye maps) from the first segment (left) to the last segments to reach minimal volume from a responder patient: A) Left ventricular systolic dysfunction without transmural scar but antero-septal scar. B) Electrical and mechanical bull's eyes of the same patients after cardiac resynchronization therapy showing a significant decrease in the timing and propagation of both electrical activation and mechanical timings with cardiac resynchronization therapy and how the patterns are changed. Red lines represent left ventricular segments with myocardial scar. CRT, cardiac resynchronization therapy; LV, left ventricular.

A) LV dysfunction

Time step=5ms



Time step=9ms



B) LV dysfunction after CRT optimization

Time step=5ms



Time step=7ms



**Figure 10.** Sequences of electrical activation (upper bull's-eye maps) from the electrical onset (left) to the end (right) and maximal mechanical motion (lower bull's-eye maps) from the first segment (left) to the last segments to reach minimal volume from a responder patient: A) Left ventricular systolic dysfunction without transmural scar and with anterolateral propagation line block. B) Electrical and mechanical bull's eyes of the same patients after cardiac resynchronization therapy showing a decrease in the timing and propagation of both electrical activation and mechanical timings with cardiac resynchronization therapy and how the patterns are changed. CRT, cardiac resynchronization therapy; LV, left ventricular.

A) LV dysfunction

Time step=5ms




Time step=22ms



B) LV dysfunction after CRT optimization

Time step=5ms




Time step=12ms



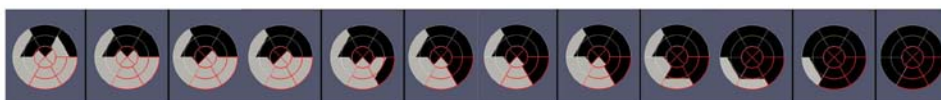**Figure 11.** Sequences of electrical activation (upper bull's-eye maps) from the electrical onset (left) to the end (right) and maximal mechanical motion (lower bull's-eye maps) from the first segment (left) to the last segments to reach minimal volume from a responder patient: A) Left ventricular systolic dysfunction without transmural scar. B) Electrical and mechanical bull's eyes of the same patients after cardiac resynchronization therapy showing a significant decrease in the timing and propagation of both electrical activation and mechanical timings with cardiac resynchronization therapy and how the patterns are changed. CRT, cardiac resynchronization therapy; LV, left ventricular.

### A) LV dysfunction: Scar tissue

Time step=5ms



Time step=17ms



### B) LV dysfunction after CRT optimization: Scar tissue

Time step=5ms



Time step=19ms



**Figure 12.** Sequences of electrical activation (upper bull's-eye maps) from the electrical onset (left) to the end (right) and maximal mechanical motion (lower bull's-eye maps) from the first segment (left) to the last segments to reach minimal volume from a non-responder patient: A) Left ventricular systolic dysfunction with transmural scar at the posterolateral wall. B) Electrical and mechanical bull's eyes of the same patients after cardiac resynchronization therapy showing no decrease in the timing and propagation of electrical activation or mechanical timings with cardiac resynchronization therapy. Red lines represent left ventricular segments with myocardial scar. CRT, cardiac resynchronization therapy; LV, left ventricular.