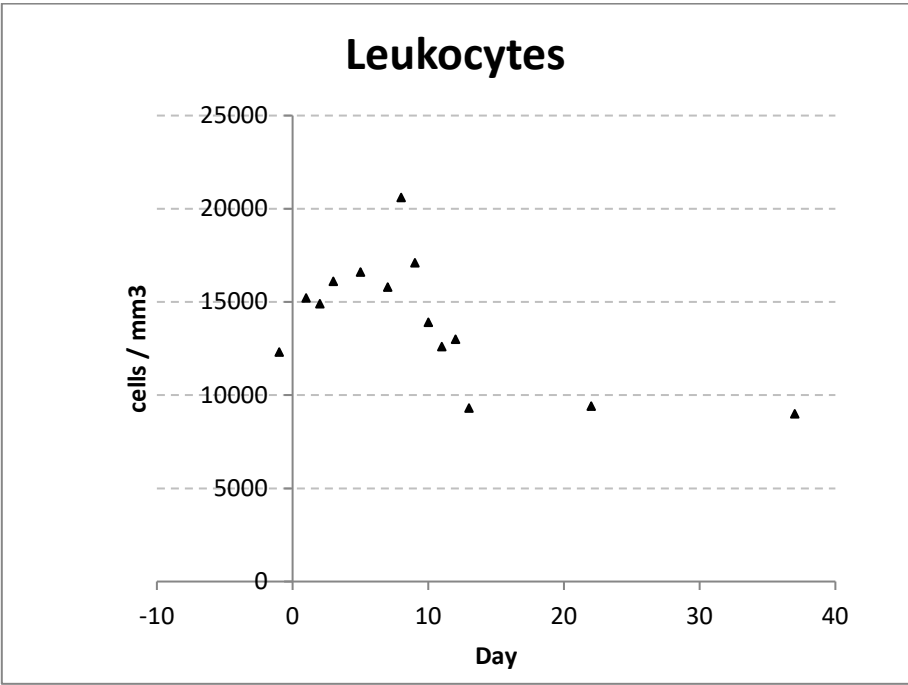


SUPPLEMENTARY MATERIAL

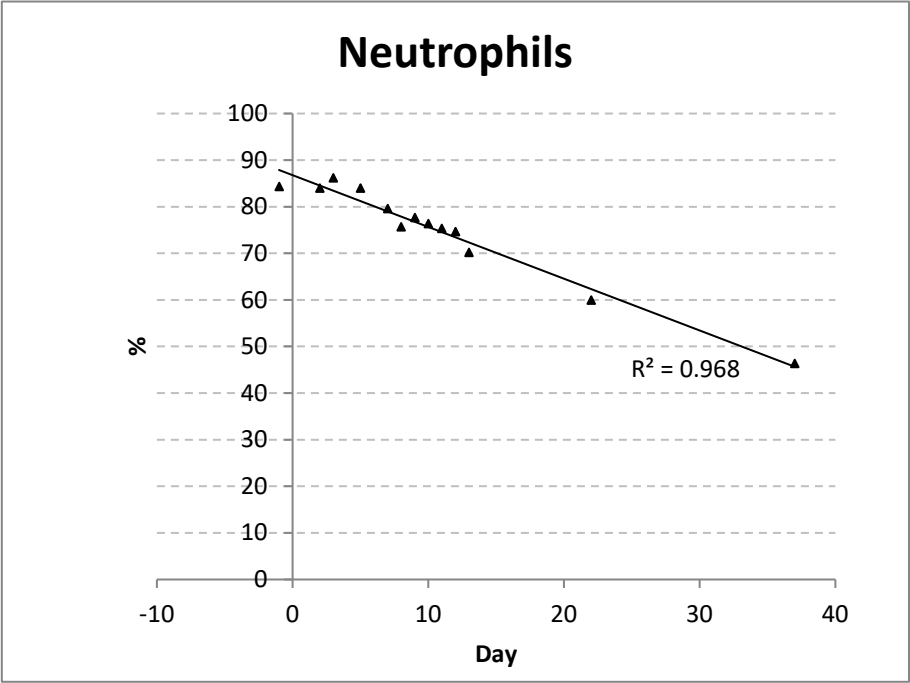
Figure S1

Evolution of hematological parameters since onset, through hospitalization period and after discharge

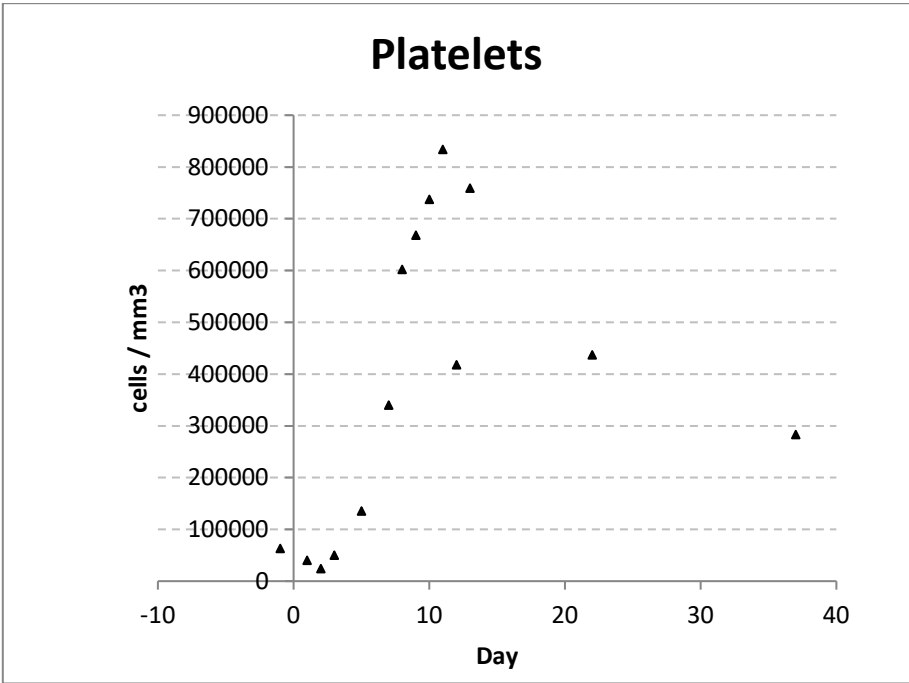
Panel a. Leukocytes



Panel b. Neutrophils



Panel c. Platelets



Panel d. Hematocrit

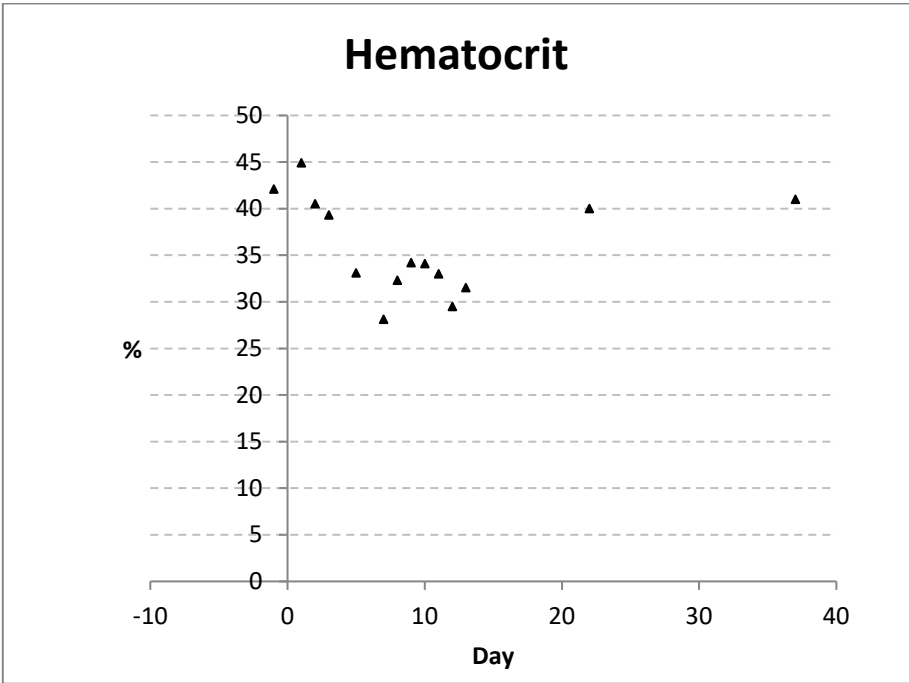
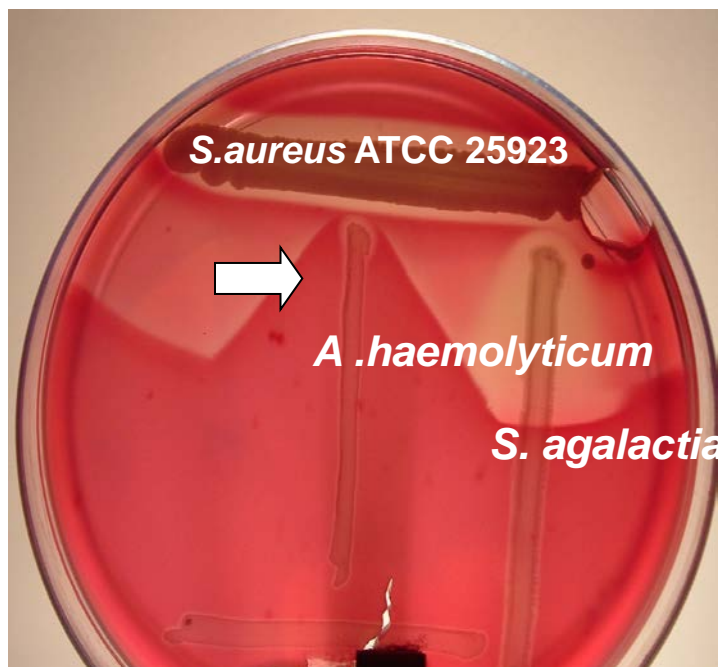


Figure S2

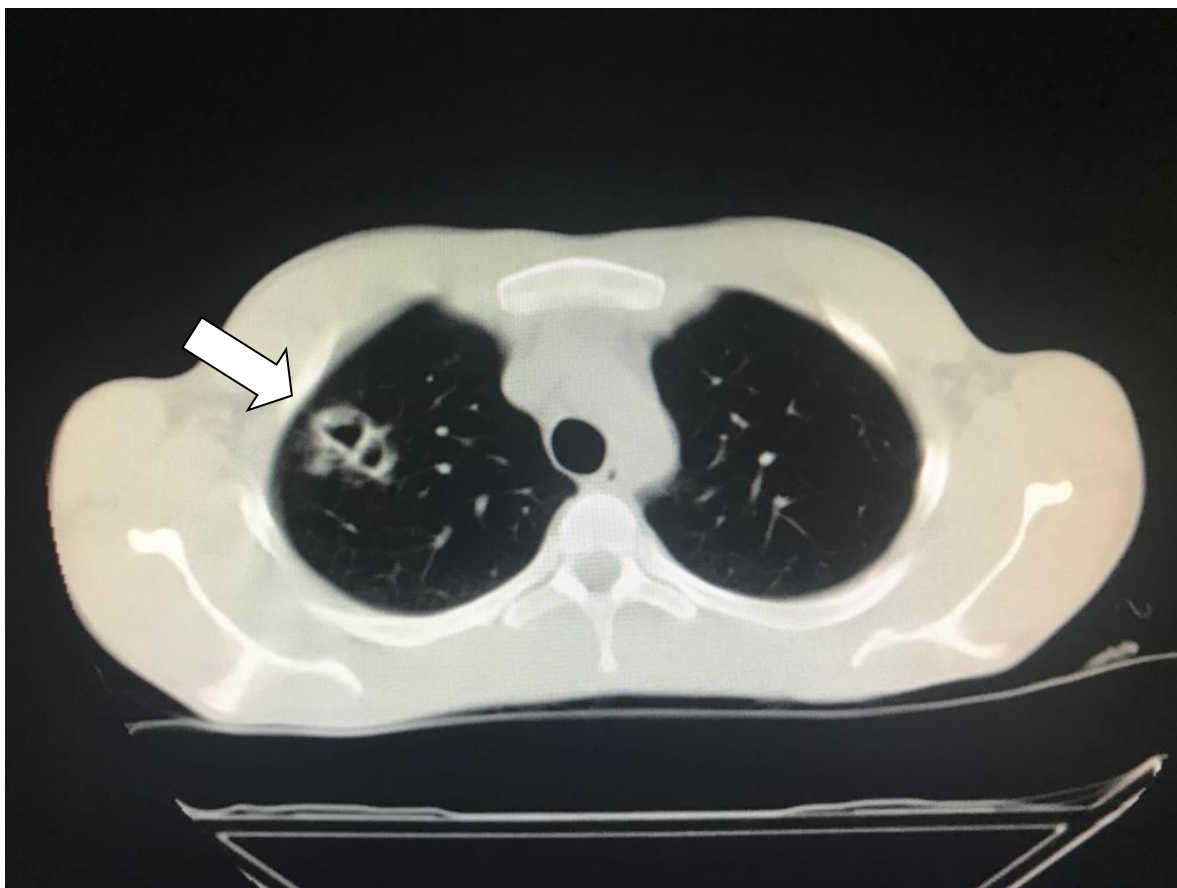
Reverse CAMP test



Arrow: narrowing of the hemolytic zone produced by staphylococcal β -lysine.

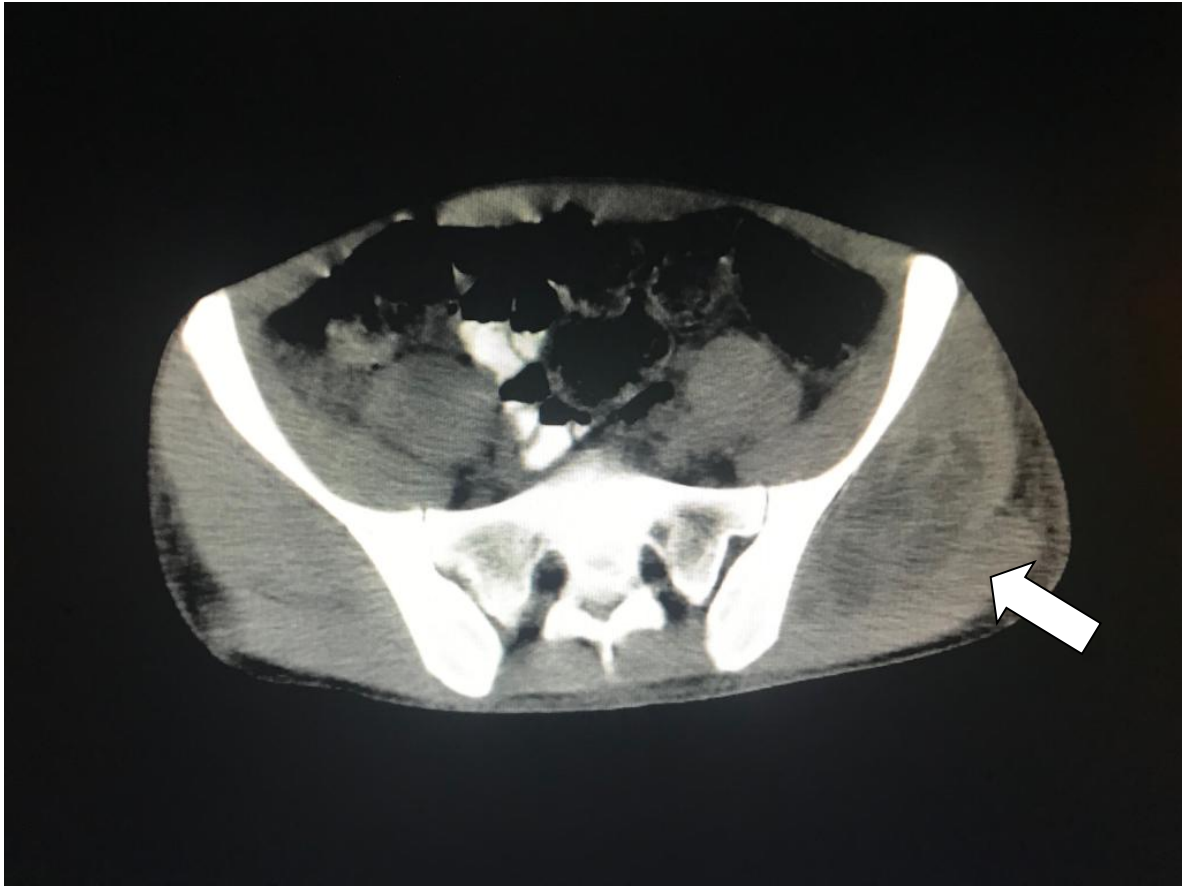
Figure S3

Panel a. Computer tomography¹ showing two images of small cavitated subpleural abscesses in the right lung (arrow)



¹Elscint CT Twin Flash CT Scanner.

Panel b. Computer tomography¹ showing an abscessed collection of 10 x 6 cm in the left gluteus medius muscle (arrow) that displaced and compressed surrounding structures



¹Elscint CT Twin Flash CT Scanner.