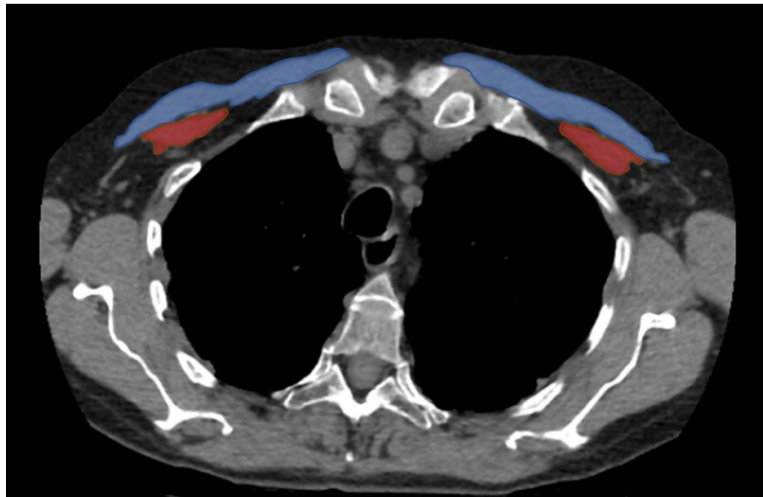
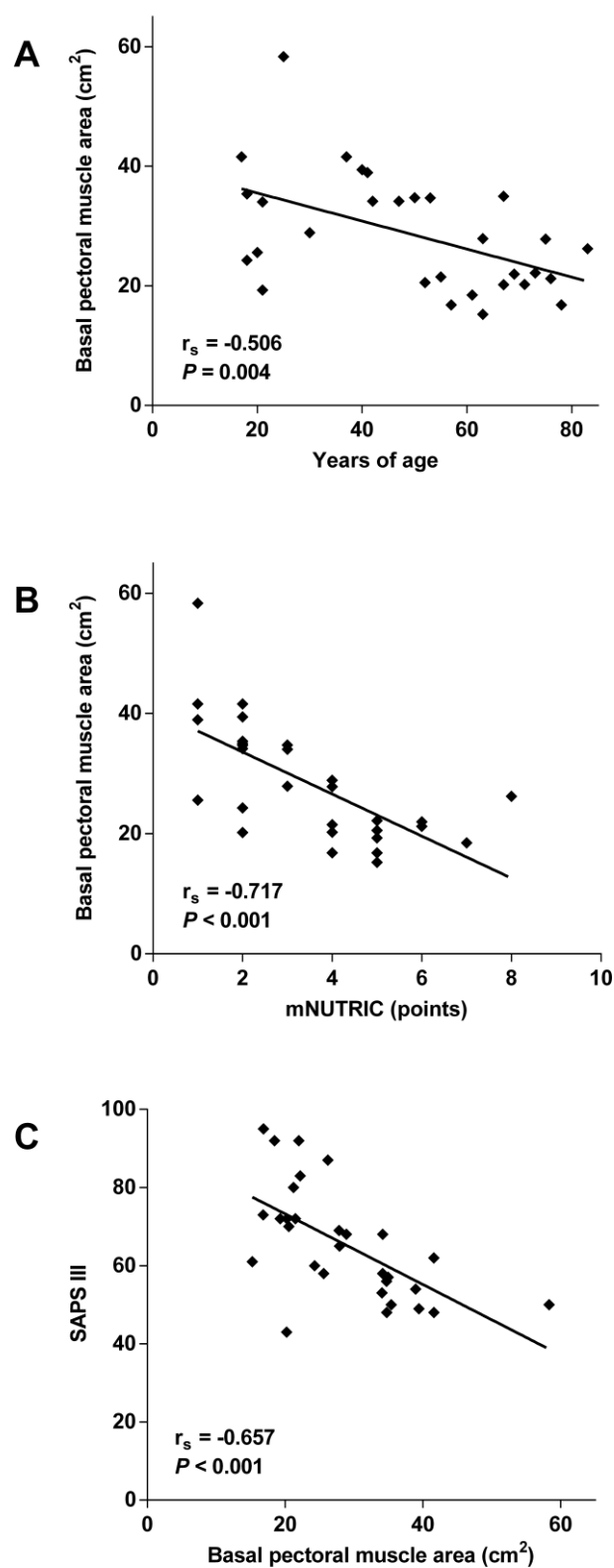


Development of pectoral muscle atrophy in critically ill patients.



Supplementary Figure 1. Sample computed tomography scan used for measurement of major (blue) and minor (red) pectoral muscles' area.



Supplementary Figure 2. Bivariate correlation between pectoral muscle area on admission and patients' age (A), mNUTRIC score (B) or SAPS III (C).